

Mineral trioxide aggregate pulpotomies

A case series outcomes assessment

David E. Witherspoon, BDS, MS; Joel C. Small, DDS; Gary Z. Harris, DDS

Traumatic injuries and dental caries are the greatest challenges to the integrity of the developing tooth. Both can cause the dental pulp to undergo irreversible damage, causing necrosis of the pulpal tissues, which can result in the arrest of normal root development. Abnormal root development will have an impact on the long-term prognosis for tooth retention.¹⁻⁴ The primary goal of treatment, therefore, should be to maintain pulp vitality so that normal root development can occur. By maintaining pulp vitality, apexogenesis can occur.⁵⁻⁸ This is the preferred treatment because it promotes healing by regeneration rather than repair. Pulpotomy involves the surgical removal of a portion of an affected vital coronal pulp tissue, while the clinician leaves the radicular tissue in situ to allow for normal root development.

PULPOTOMIES: A REVIEW OF THE LITERATURE

Several materials have been advocated to induce normal root development.⁹⁻¹¹ To date, the material of choice has been calcium hydroxide.¹²⁻¹⁸ In the past decade, an alternative material called mineral trioxide aggregate (MTA) became available for use in pulpal procedures. Clinicians should evaluate

ABSTRACT

Background. The greatest threats to developing teeth are dental caries and traumatic injury. A primary goal of all restorative treatment is to maintain pulp vitality so that normal root development or apexogenesis can occur. If pulpal exposure occurs, then a pulpotomy procedure aims to preserve pulp vitality to allow for normal root development. Historically, calcium hydroxide has been the material of choice for pulpotomy procedures. Recently, an alternative material called mineral trioxide aggregate (MTA) has demonstrated the ability to induce hard-tissue formation in pulpal tissue. The authors describe the clinical and radiographic outcome of a series of cases involving the use of MTA in pulpotomy procedures.

Methods. Twenty-three cases in 18 patients were treated with MTA pulpotomy procedures in an endodontic private practice. All of the patients had been referred to the practice for diagnosis and treatment of a symptomatic tooth. All of the authors provided treatment. Pulpal exposures were either due to caries or complicated enamel dentin fractures.

Results. Nineteen teeth in 14 patients were available for recall. The mean time of recall was 19.7 months. Of the 19 cases, 15 involved healed teeth, and three involved teeth that were healing. One of 19 cases involved a tooth with persistent disease.

Conclusions. MTA may be useful as a substitute for calcium hydroxide in pulpotomy procedures. Further research, however, is required to clarify this conclusion.

Clinical Implications. MTA conceivably could replace calcium hydroxide as the material of choice for pulpotomy procedures, if future research continues to show promising results.

Key Words. Pulpotomy; mineral trioxide aggregate; apexogenesis. *JADA 2006;137:610-8.*

Dr. Witherspoon is in private practice limited to endodontics, Plano, Texas. Address reprint requests to Dr. Witherspoon at North Texas Endodontic Associates, 5800 Coit Road, Suite 200, Plano, Texas 75023, e-mail "dewspoon@ntendo.com".

Dr. Small is in private practice limited to endodontics, Plano, Texas.

Dr. Harris is in private practice limited to endodontics, Sherman, Texas.

several elements when choosing a material to be used in vital pulp treatment. These elements include the ability of the material to kill bacteria, induce mineralization and establish a bacteria-tight seal.

Calcium hydroxide. Calcium hydroxide is a white, crystalline, slightly soluble basic salt that dissociates into calcium ions and hydroxyl ions in solution and exhibits a high alkalinity (pH 11). It is used in both setting and nonsetting forms in dentistry. Codman was the first to use calcium hydroxide in pulpal treatment.¹⁹ Dentists also use calcium hydroxide because of its antimicrobial properties^{20,21} and its ability to induce hard-tissue formation.²²

Mineralization. Researchers have shown that calcium hydroxide forms a dentin bridge when placed in contact with pulpal tissues. Calcium hydroxide must be in contact with the tissue for mineralization to occur.²³ Initially, a necrotic zone is formed adjacent to the material, and, depending on the pH of the calcium hydroxide material, a dentin bridge is formed directly against the necrotic zone or the necrotic zone is resorbed and replaced by a dentin bridge.²⁴⁻²⁸ The barrier is not always complete.¹⁶ The calcium ions in the calcium hydroxide do not become incorporated in the hard tissue that forms.^{29,30} Calcium hydroxide is an initiator rather than a substrate for repair.³¹

Several theories exist as to how calcium hydroxide induces hard-tissue formation. These include the high alkalinity (a pH of 11), which produces a favorable environment for the activation of alkaline phosphatase, an enzyme involved in mineralization. The calcium ions reduce the permeability of new capillaries formed in repairing tissue, decreasing the amount of intercellular fluid and increasing the concentration of calcium ions derived from the blood supply at the mineralization front. This may have two effects on the mineralization process; it may provide a source of calcium ions for mineralization, and it may stimulate the activity of calcium-dependent pyrophosphatase, which reduces the level of mineralization inhibitory pyrophosphate ions within the tissues.³¹⁻³³

Antimicrobial effect. The antimicrobial effect of pulpotomy materials relates to the ability of the material to kill existing bacteria and prevent the future leakage of bacteria from the oral environment into the pulp. The antimicrobial properties of calcium hydroxide are derived from several fac-

tors. The high pH produces an environment that is not conducive to bacteria growth. There are three mechanisms by which calcium hydroxide induces bacterial lysis:

- the hydroxyl ions destroy phospholipids so the cellular membrane is destroyed;
- the high alkalinity breaks down ionic bonds so that bacterial proteins are denatured;
- the hydroxyl ions react with bacterial DNA, inhibiting replication.³³

Calcium hydroxide treatment also has been shown to decrease the effect of bacterial-associated lipopolysaccharide (LPS).²¹ It can hydrolyze the lipid moiety of bacterial LPS and is able to eliminate the ability of LPS to stimulate tumor-necrosis factor-alpha production in peripheral blood monocytes.³⁴ These actions decrease the ability of bacteria to cause tissue destruction.

The ability to prevent penetration of bacteria into the pulp affects pulp survival significantly.^{35,36} Initially, the two paste calcium hydroxide systems were believed to have the ability to resist bacterial penetration; however, their ability to continue to do so has been called into question.^{35,37,38} The adhesive bond of calcium hydroxide liners to dentin is weak, and adhesive resin materials do not bond to the surface of the material.³⁵ The incidence of bacterial leakage when calcium hydroxide is used in pulpal procedures has been reported as 47.0 percent.³⁹ This was significantly greater than the leakage associated with bonded resin restorations. The severity of pulpal inflammation was shown to increase with the presence of bacteria.

Outcomes. Several studies have assessed the outcomes of calcium hydroxide in vital pulpal treatment. Generally, as the length of the follow-up period increased, the success rate decreased. At the five- and 10-year follow-ups, pulp capping of cariously exposed teeth resulted in a failure rate of 44.5 percent and 79.7 percent, respectively.⁴⁰ In teeth with carious exposures treated with calcium hydroxide pulpotomies, healing teeth ranged from approximately 50 to 92 percent.⁴¹⁻⁴³

A study examining 41 teeth with carious pulpal exposures (with or without periradicular changes seen on radiographic examination) treated with pulpotomy and calcium hydroxide reported a healing rate of 87 to 79 percent.⁴¹ The healing rate in teeth with pre-existing pain, however, was approximately 50 percent. The follow-up period varied from six to eight months. In a similar

study, investigators found that 26 permanent vital molars with asymptomatic carious pulp exposures and periradicular involvement were treated with calcium hydroxide pulpotomies.⁴² The patients ranged in age from 10 to 24 years, and 24 teeth (92 percent) achieved healing status. The observation period after pulpotomy treatment was 16 to 72 months; however, investigators followed only 12 teeth beyond 24 months. The mean follow-up period was not reported in the study. In another study, 37 posterior teeth with deep carious lesions that were exposed during caries removal were treated with calcium hydroxide pulpotomies.⁴³ The patients ranged in age from 6 to 15 years. Six teeth had widened periodontal ligament spaces periradicularly and a history of temporary pain. None of the other teeth had signs and symptoms of pulpal or periradicular inflammation or infection. The healing rate was 89 percent, and the follow-up period ranged from 24 to 140 months, with a mean of 56 months.

The healing rates in teeth with traumatic exposures that were treated with calcium hydroxide ranged from 72 to 96 percent.⁴⁴⁻⁴⁸ Fuks and colleagues⁴⁹ reported the long-term success of partial pulpotomies in complicated crown fractures in permanent incisors that were followed for 7.5 to 11 years at 87.5 percent.

MTA. MTA is composed of tricalcium silicate, tricalcium aluminate, tricalcium oxide and silicate oxide. Hydration of the powder results in a colloidal gel composed of calcium oxide crystals in an amorphous structure: 33 percent calcium, 49 percent phosphate, 6 percent silica, 3 percent chloride and 2 percent carbon. This gel solidifies into a hard structure in less than three hours.⁵⁰ It has a compressive strength equal to zinc oxide-eugenol with polymer reinforcement (Caulk IRM Intermediate Restorative Material, Dentsply, York, Pa.) and all-purpose lining and cement (SuperEBA, Harry J. Bosworth, Skokie, Ill.) but less than that of amalgam. It is available commercially as ProRoot MTA (Dentsply Tulsa Dental, Tulsa, Okla.) and has been advocated for use in vital pulp therapy.⁵¹⁻⁵⁵

Mineralization. MTA has demonstrated the ability to induce hard-tissue formation in pulpal tissues,^{51,53,56-59} and it promotes rapid cell growth in vitro.⁶⁰ Compared with calcium hydroxide, MTA has demonstrated a greater ability to maintain the integrity of pulp tissue.^{51,61} Histologic evaluation of pulpal tissue in animals and humans demonstrated that MTA produces a

thicker dentinal bridge, less inflammation, less hyperemia and less pulpal necrosis compared with calcium hydroxide.^{51,58} MTA also appears to induce the formation of a dentin bridge at a faster rate than does calcium hydroxide. The process by which MTA acts to induce dentin bridge formation, however, is not known. Holland and colleagues⁶² theorized that the tricalcium oxide in MTA reacts with tissue fluids to form calcium hydroxide, resulting in hard-tissue formation in a manner similar to that of calcium hydroxide.

Antibacterial effect. According to Torabinejad and colleagues,⁶³ MTA has an antibacterial effect on some facultative bacteria but no effect on strict anaerobic bacteria. This limited antibacterial effect is less than that demonstrated by calcium hydroxide pastes. The ability of MTA to resist the penetration of microorganisms appears to be high. In leakage studies, MTA frequently performs better than amalgam, IRM or SuperEBA.⁶⁴⁻⁶⁸ Compared with ideally placed resin-based composite, MTA leakage patterns are similar.^{69,70} Furthermore, the presence of blood has little impact on the degree of leakage.^{67,71}

Outcomes. To date, the clinical assessment of MTA has been restricted to case reports. In one, researchers performed partial pulpotomies in two cases of dens evaginatus.⁷² After six months, researchers removed the teeth as part of planned orthodontic treatment. Histologic examination of these teeth showed an apparent continuous dentin bridge formation in both teeth, and the pulps were free of inflammation.

In this article, we describe the clinical and radiographic outcome of a series of cases using MTA in pulpotomy procedures.

MATERIALS AND METHODS

We treated 23 teeth (cases 1-23) in 18 patients between 1999 and 2003 in an endodontic private practice (Tables 1 and 2, page 614). The patients had no contraindication to dental treatment. We took all of the radiographs using a digital radiographic system according to the manufacturer's recommendations, and we conducted pulpal vitality tests to establish a pulpal diagnosis.

The treatment followed the standard pulpotomy procedure of removing the pulp to the stump level using a coarse high-speed diamond bur with copious irrigation. We used rubber dam isolation in all cases. In each case, we achieved hemostasis by irrigating pulp tissue with 2 milliliters of 6

TABLE 1

Individual patient data.						
CASE NO.	PATIENT NO.	PATIENT AGE (YEARS)	TOOTH NO.	OUTCOME	DIAGNOSIS	RECALL (MONTHS)
1	1	10	19	Healing	IP/C*	19
2	1	10	30	Healing	IP/C	19
3	2	14	31	Healed	IP/C	13
4	3	7.5	14	Patient not available for recall	IP/C	Patient not available for recall
5	4	16	8	Healed	IP/T/CEDF†	12
6	5	13	15	Healed	IP/C	12
7	6	11	13	Healed	IP/C	29
8	7	12	18	Healed	IP/C	11
9	8	8	8	Healed	IP/T/CEDF	15
10	8	8	9	Healed	IP/T/CEDF	15
11	9	11	18	Persistent disease	IP/C	13
12	10	8	14	Patient not available for recall	IP/C	Patient not available for recall
13	11	9	9	Healed	IP/T/CEDF	25
14	12	8	8	Patient not available for recall	IP/T/CEDF	Patient not available for recall
15	13	7	3	Healed	IP/C	33
16	13	8	19	Healed	IP/C	18
17	13	8	30	Healed	IP/C	17
18	14	15	31	Healed	IP/C	6
19	15	8	30	Healed	IP/C	32
20	16	9	8	Healed	IP/T/CEDF	13
21	16	9	9	Healed	IP/T/CEDF	13
22	17	9.5	14	Patient not available for recall	IP/C	Patient not available for recall
23	18	8.5	30	Healing	IP/C	53

* IP/C: Irreversible pulpitis with caries exposure.
† IP/T/CEDF: Irreversible pulpitis with a complicated enamel dentin fracture due to a traumatic injury.

percent sodium hypochlorite⁷³ for approximately one minute. We avoided applying pressure to the pulp stumps, as it could crush the delicate tissue, the cotton from the cotton pellets used could get in the tissue and a dentin chip could be forced into the pulp tissue, all of which could have a negative effect on healing. We placed an approximately 2-millimeter-thick layer of MTA (mixed according to the manufacturer's recommendations) over the exposed pulpal tissue. We took a final radiograph after we removed the rubber dam. Finally, we referred the patients back to

their restorative dentists.

Recall intervals were approximately three months, and we followed all of the cases for as long as possible. Recall appointments included subjective history assessment, thermal pulpal testing, percussion assessment and a radiographic evaluation. We categorized cases as "healed," "healing" or "persistent disease" (Box).

Statistical analysis. We used the Kaplan-Meier method to assess the probability of tooth survival (that is, whether the tooth required any further treatment) and tooth healing.

TABLE 2

Summary data.	
CATEGORY	DATA
Age (Years)	
Range	7 to 16
Mean	9.9
Mode	8
Median	9
Recall	
Total no. (%)	19 (83)
Mean (Months)	19.7
Mode (Months)	13
Median (Months)	17
Range (Months)	6 to 53
Outcome (No. of Teeth [%])	
Healed	15 (79)
Healing	3 (16)
Persistent disease	1 (5)
Diagnosis (No. of Teeth)	
Irreversible pulpitis due to caries	16
Irreversible pulpitis with a complicated enamel dentin fracture due to a traumatic injury	7
Tooth Type (No. of Teeth)	
Maxillary molar	5
Mandibular molar	10
Maxillary premolar	1
Mandibular premolar	0
Maxillary incisor	7
Mandibular incisor	0

RESULTS

Nineteen cases in 14 patients were available for recall (Table 1). The mean time of recall was 19.7 months (Table 2). The age range of patients was from 7 to 16 years, with a mean age of 9.9 years. Thirteen of the 19 cases (68.4 percent) available for recall had a diagnosis of irreversible pulpitis with a caries exposure (Table 1). Of these 13 cases, 70 percent healed, 23 percent were in the healing category, and 7 percent had persistent disease. Molars were the most frequently treated tooth type. Of the 19 cases, 15 involved teeth that

BOX

Case categories.
<p>HEALED</p> <ul style="list-style-type: none"> ■ No history of pain, discomfort or altered sensation ■ Thermal test results for the treated tooth similar to those for contralateral control teeth ■ Radiographic appearance of the tooth consistent with developmental age <p>HEALING</p> <ul style="list-style-type: none"> ■ No history of pain, discomfort or altered sensation ■ No response of the treated tooth to thermal testing or electric pulp testing ■ Radiographic appearance of the tooth consistent with developmental age <p>PERSISTENT DISEASE</p> <ul style="list-style-type: none"> ■ A history of pain, discomfort or altered sensation ■ No response of the treated tooth to thermal testing or electric pulp testing ■ Radiographic appearance of the tooth inconsistent with developmental age

healed (Figures 1 and 2), and three involved teeth that were healing (Figures 3 and 4). One of the 19 cases involved a tooth with persistent disease.

The probability of tooth survival at 12 months was 1.0 at a 95 percent confidence interval; the probability decreased to 0.95 at the termination point of the evaluation (Figure 5, page 616). The probability of a tooth being completely healed at 20 months was 0.55 at a 95 percent confidence interval (Figure 6, page 616).

DISCUSSION

The primary objective of vital pulp therapy in teeth with incomplete root formation is to promote normal development of the root complex. There are several long-term advantages of this treatment over apexification treatment. The tooth structure that is formed is of great quantity, and its composition appears to have greater structural integrity.³ The result is that the fully developed tooth is more resistant to vertical root fractures.⁴ The ideal material for vital pulp treatment should resist bacterial leakage and stimulate the remaining pulp tissue to return to a healthy state promoting the formation of dentin.

Calcium hydroxide has been the material of choice for such treatments.⁷⁴ The dentin formed in response to calcium hydroxide's stimulation of pulpal tissue typically ranges from a porous dentin-type material to a dentin structure that approaches that of normal dentin.⁵⁷ The type of dentin structure formed depends on a number of variables and is not predictable.³⁹ These variables

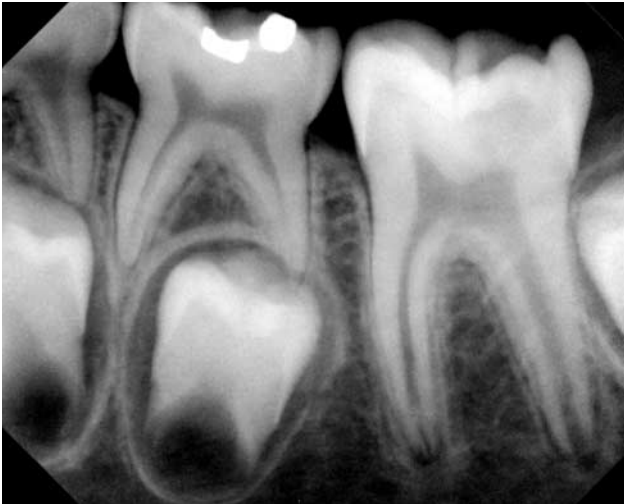


Figure 1. Preoperative radiograph of case no. 16.

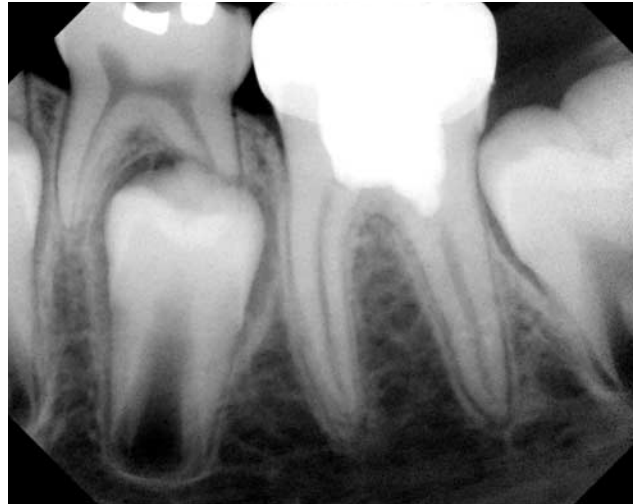

Figure 2. Postoperative radiograph of case no. 16 at 18-month recall (healed).

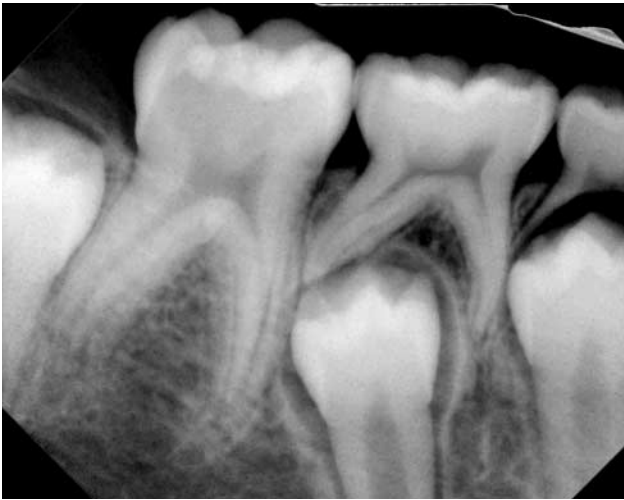

Figure 3. Preoperative radiograph of case no. 2.

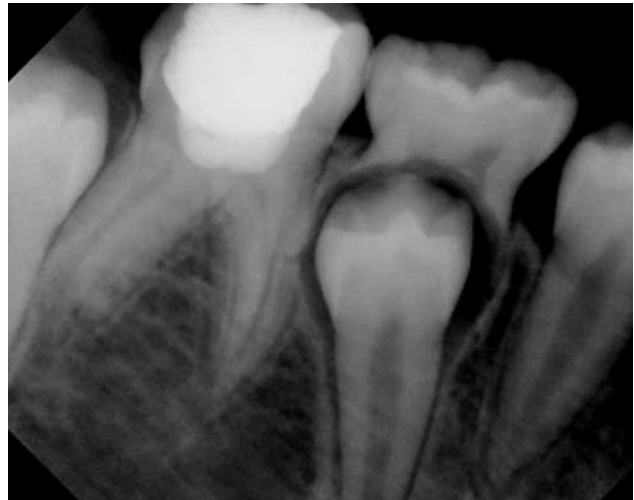

Figure 4. Postoperative radiograph of case no. 2 at 19-month recall (healing).

include the type of calcium hydroxide material used (powder mixed with water or a commercially available preparation),^{26,75,76} the degree of contact between the material and the pulp,⁷⁷ and the ability to control pulpal bleeding.⁷⁸ Calcium hydroxide also has been shown to have little resistance to bacterial leakage over the medium term in a study.⁷⁹ In *in vitro* leakage studies, MTA has resisted leakage, predictably and repeatedly.^{80,81}

In a short-term animal assessment study, MTA consistently induced the formation of dentin at a greater rate with greater structural integrity and more complete dentin bridging than did calcium hydroxide.⁶¹ Histologically, in other animal studies, MTA was considerably better at stimu-

lating reparative dentin formation and maintaining the integrity of the pulp.^{57,59} In a short-term human study using adult third molars, MTA consistently demonstrated less inflammation, hyperemia and necrosis, as well as a thicker dentinal bridge with more frequent odontoblastic layer formation, than that seen with calcium hydroxide.⁵⁸

In an outcome assessment of calcium hydroxide in vital pulp treatment, success rates ranged from 50 to 96 percent.^{41,44,49,82,83} These studies typically focused on asymptomatic teeth with deep carious lesions that resulted in a pulpal exposure or on noncarious teeth with complex enamel fractures, dentin fractures or both. Thus, the pulp had no pre-existing disease process. A 93.5 percent suc-

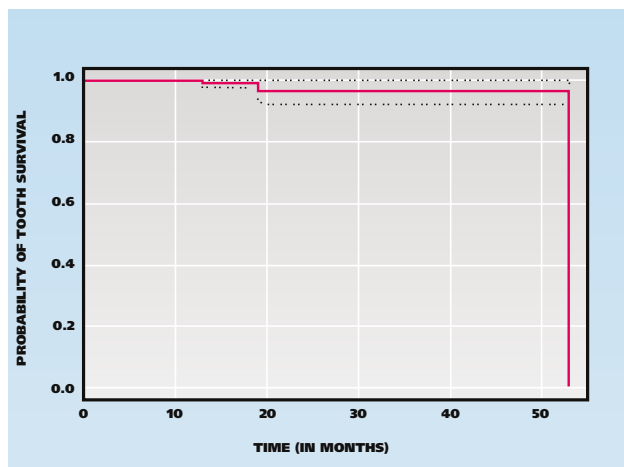


Figure 5. Kaplan-Meier method plot of probability of tooth survival.

cess rate was achieved using a calcium hydroxide partial pulpotomy technique in young posterior teeth with deep carious lesions and exposed pulps.⁴³ All of the teeth had no history of signs or symptoms and responded within normal limits to pulp testing at the time of treatment.

In another investigation, calcium hydroxide pulpotomies were used to treat successfully 24 of 26 (92 percent) permanent vital molars with carious pulp exposures and periradicular involvement in patients 10 to 24 years of age.⁴² In that study, all of the teeth initially were asymptomatic and responded within normal limits to pulp tests. Six to nine months after treatment, investigators removed the coronal restoration and assessed the sensitivity of the radicular pulp.

In such studies, the preoperative pulpal diagnosis would have been either normal or reversible pulpitis.^{42,43} A significant difference in our investigation was the painful condition of a large percentage of the teeth before treatment. Approximately 70 percent of the cases on which we reported in this series involved teeth with caries exposure and a preoperative diagnosis of irreversible pulpitis. For this group, we achieved a 100 percent success rate in terms of the primary goal of normal root development in treating such a tooth. The success rate in terms of maintaining the vitality of the tooth as assessed by a response to thermal or electrical stimulus with the original coronal restoration intact in this group was 75 percent. Only one tooth (5 percent) has required additional endodontic treatment to date. This tooth had not received an appropriate coronal restoration, and recurrent caries was evident.

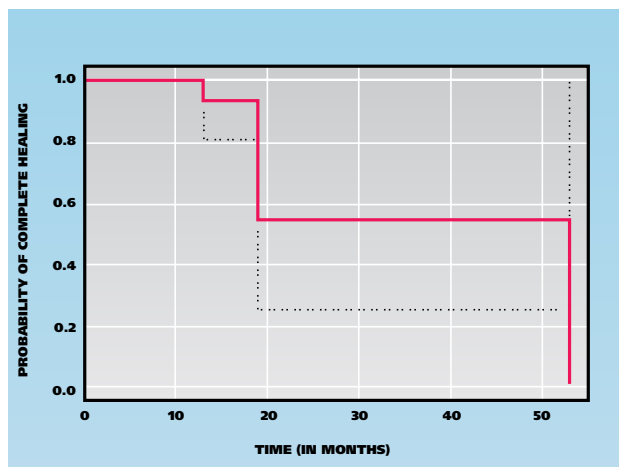


Figure 6. Kaplan-Meier method plot of probability of complete healing.

CONCLUSION

MTA may be useful as a substitute for calcium hydroxide in pulpotomy procedures. Further research, however, is needed to clarify this conclusion. ■

The authors would like to thank Dr. Martha Nunn for her statistical analysis, Dr. John D. Regan for his critical review and the staff members of North Texas Endodontic Associates for their tireless efforts in recalling patients.

1. Robertson A, Andreasen FM, Andreasen JO, Noren JG. Long-term prognosis of crown-fractured permanent incisors: the effect of stage of root development and associated luxation injury. *Int J Paediatr Dent* 2000;10(3):191-9.
2. Rabie G, Trope M, Tronstad L. Strengthening of immature teeth during long-term endodontic therapy. *Endod Dent Traumatol* 1986;2(1):43-7.
3. Katebzadeh N, Dalton BC, Trope M. Strengthening immature teeth during and after apexification. *J Endod* 1998;24:256-9.
4. Cvek M. Prognosis of luxated non-vital maxillary incisors treated with calcium hydroxide and filled with gutta-percha: a retrospective clinical study. *Endod Dent Traumatol* 1992;8(2):45-55.
5. Love RM. Effects of dental trauma on the pulp. *Pract Periodontics Aesthet Dent* 1997;9:427-36; quiz 38.
6. Shabahang S, Torabinejad M. Treatment of teeth with open apices using mineral trioxide aggregate. *Pract Periodontics Aesthet Dent* 2000;12:315-20; quiz 22.
7. Webber RT. Apexogenesis versus apexification. *Dent Clin North Am* 1984;28:669-97.
8. Massler M. Preventive endodontics: vital pulp therapy. *Dent Clin North Am* 1967;11:663-73.
9. Horsted-Bindslev P, Vilkinis V, Sidlauskas A. Direct capping of human pulps with a dentin bonding system or with calcium hydroxide cement. *Oral Surg Oral Med Oral Pathol Oral Radiol Endod* 2003;96:591-600.
10. Trope M, McDougal R, Levin L, May KN Jr, Swift EJ Jr. Capping the inflamed pulp under different clinical conditions. *J Esthet Restor Dent* 2002;14:349-57.
11. Kiba H, Hayakawa T, Nakanuma K, Yamazaki M, Yamamoto H. Pulpal reactions to two experimental bonding systems for pulp capping procedures. *J Oral Sci* 2000;42(2):69-74.
12. Ulmanky M, Sela J, Langer M, Yaari A. Response of pulpotomy wounds in normal human teeth to successively applied Ledermix and Calxyl. *Arch Oral Biol* 1971;16:1393-8.
13. Schroder U, Granath LE. Scanning electron microscopy of hard tissue barrier following experimental pulpotomy of intact human teeth and capping with calcium hydroxide. *Odontol Revy* 1972;23:211-20.
14. Schroder U. Evaluation of healing following experimental pulpotomy of intact human teeth and capping with calcium hydroxide.

Odontol Revy 1972;23:329-40.

15. Holland R, de Souza V, de Mello W, Nery MJ, Bernabe PF, Otoboni Filho JA. Healing process after pulpotomy and covering with calcium hydroxide, Dycal or MPC: histological study in dog teeth. *Rev Fac Odontol Aracatuba* 1978;7(2):185-91.

16. Holland R, de Souza V, de Mello W, Nery MJ, Bernabe PF, Otoboni Filho JA. Permeability of the hard tissue bridge formed after pulpotomy with calcium hydroxide: a histologic study. *JADA* 1979;99:472-5.

17. Stanley HR. Criteria for standardizing and increasing credibility of direct pulp capping studies. *Am J Dent* 1998;11(special number):S17-34.

18. Haskell EW, Stanley HR, Chellemi J, Stringfellow H. Direct pulp capping treatment: a long-term follow-up. *JADA* 1978;97:607-12.

19. Codman WW. Ossification of the pulp of a tooth. *Newsletter* 1851;IV:90.

20. King JB Jr., Crawford JJ, Lindahl RL. Indirect pulp capping: a bacteriological study of deep carious dentine in human teeth. *Oral Surg Oral Med Oral Pathol* 1965;20:663-9.

21. Safavi KE, Nichols FC. Effect of calcium hydroxide on bacterial lipopolysaccharide. *J Endod* 1993;19(2):76-8.

22. Mitchell DF, Shankwalker GB. Osteogenic potential of calcium hydroxide and other materials in soft tissue and bone wounds. *J Dent Res* 1958;37:1157-63.

23. Rasmussen P, Mjor IA. Calcium hydroxide as an ectopic bone inductor in rats. *Scand J Dent Res* 1971;79(1):24-30.

24. Stanley HR, Lundy T. Dycal therapy for pulp exposures. *Oral Surg Oral Med Oral Pathol* 1972;34:818-27.

25. Tronstad L. Reaction of the exposed pulp to Dycal treatment. *Oral Surg Oral Med Oral Pathol* 1974;38:945-53.

26. Heys DR, Cox CF, Heys RJ, Avery JK. Histological considerations of direct pulp capping agents. *J Dent Res* 1981;60:1371-9.

27. Pitt Ford TR. Pulpal response to a calcium hydroxide material for capping exposures. *Oral Surg Oral Med Oral Pathol* 1985;59(2):194-7.

28. Tagger M, Tagger E. Pulp capping in monkeys with Reolit and Life, two calcium hydroxide bases with different pH. *J Endod* 1985;11:394-400.

29. Sciaky I, Pisanti S. Localization of calcium placed over amputated pulps in dogs' teeth. *J Dent Res* 1960;39:1128-32.

30. Pisanti S, Sciaky I. Origin of calcium in the repair wall after pulp exposure in the dog. *J Dent Res* 1964;43:641-4.

31. Foreman PC, Barnes IE. Review of calcium hydroxide. *Int Endod J* 1990;23:283-97.

32. Heithersay GS. Calcium hydroxide in the treatment of pulpless teeth with associated pathology. *J Br Endod Soc* 1975;8(2):74-93.

33. Siqueira JF Jr, Lopes HP. Mechanisms of antimicrobial activity of calcium hydroxide: a critical review. *Int Endod J* 1999;32:361-9.

34. Barthel CR, Levin LG, Reisner HM, Trope M. TNF-alpha release in monocytes after exposure to calcium hydroxide treated *Escherichia coli* LPS. *Int Endod J* 1997;30(3):155-9.

35. Cox CF, Bogen G, Kopel HM, Ruby JD. Repair of pulpal injury by dental materials. In: Hargreaves KM, Goodis HE, Seltzer S, eds. *Seltzer and Bender's dental pulp*. Chicago: Quintessence; 2002:325-44.

36. Stanley H. Calcium hydroxide and vital pulp therapy. In: Hargreaves KM, Goodis HE, Seltzer S, eds. *Seltzer and Bender's dental pulp*. Chicago: Quintessence; 2002:309-24.

37. Murray PE, Lumley PJ, Smith AJ, Ross HF. The influence of sample dimensions on hydroxyl ion release from calcium hydroxide products. *Endod Dent Traumatol* 2000;16:251-7.

38. Cox CF, Bergenholtz G, Heys DR, Syed SA, Fitzgerald M, Heys RJ. Pulp capping of dental pulp mechanically exposed to oral microflora: a 1-2 year observation of wound healing in the monkey. *J Oral Pathol* 1985;14(2):156-68.

39. Murray PE, Hafez AA, Smith AJ, Cox CF. Hierarchy of pulp capping and repair activities responsible for dentin bridge formation. *Am J Dent* 2002;15:236-43.

40. Barthel CR, Rosenkranz B, Leuenberg A, Roulet JF. Pulp capping of carious exposures: treatment outcome after 5 and 10 years—a retrospective study. *J Endod* 2000;26:525-8.

41. Teixeira LS, Demarco FF, Coppola MC, Bonow ML. Clinical and radiographic evaluation of pulpotomies performed under intrapulpal injection of anaesthetic solution. *Int Endod J* 2001;34:440-6.

42. Caliskan MK. Pulpotomy of carious vital teeth with periapical involvement. *Int Endod J* 1995;28:172-6.

43. Mejare I, Cvek M. Partial pulpotomy in young permanent teeth with deep carious lesions. *Endod Dent Traumatol* 1993;9:238-42.

44. Cvek M. A clinical report on partial pulpotomy and capping with calcium hydroxide in permanent incisors with complicated crown fracture. *J Endod* 1978;4:232-7.

45. Ravn JJ. Follow-up study of permanent incisors with complicated

crown fractures after acute trauma. *Scand J Dent Res* 1982;90:363-72.

46. Cox CF, Bergenholtz G, Fitzgerald M, et al. Capping of the dental pulp mechanically exposed to the oral microflora: a 5 week observation of wound healing in the monkey. *J Oral Pathol* 1982;11:327-39.

47. Fuks AB, Cosack A, Klein H, Eidelman E. Partial pulpotomy as a treatment alternative for exposed pulps in crown-fractured permanent incisors. *Endod Dent Traumatol* 1987;3(3):100-2.

48. Gelbier MJ, Winter GB. Traumatized incisors treated by vital pulpotomy: a retrospective study (published correction appears in *Br Dent J* 1988;164[11]:361). *Br Dent J* 1988;164(10):319-23.

49. Fuks AB, Gavra S, Chosack A. Long-term followup of traumatized incisors treated by partial pulpotomy. *Pediatr Dent* 1993;15:334-6.

50. Torabinejad M, Hong CU, McDonald F, Pitt Ford TR. Physical and chemical properties of a new root-end filling material. *J Endod* 1995;21:349-53.

51. Ford TR, Torabinejad M, Abedi HR, Bakland LK, Kariyawasam SP. Using mineral trioxide aggregate as a pulp-capping material. *JADA* 1996;127:1491-4.

52. Torabinejad M, Chivian N. Clinical applications of mineral trioxide aggregate. *J Endod* 1999;25(3):197-205.

53. Andelin WE, Shabahang S, Wright K, Torabinejad M. Identification of hard tissue after experimental pulp capping using dentin sialoprotein (DSP) as a marker. *J Endod* 2003;29:646-50.

54. Bakland LK. Management of traumatically injured pulps in immature teeth using MTA. *J Calif Dent Assoc* 2000;28:855-8.

55. Schmitt D, Lee J, Bogen G. Multifaceted use of ProRoot MTA root canal repair material. *Pediatr Dent* 2001;23:326-30.

56. Holland R, de Souza V, Murata SS, et al. Healing process of dog dental pulp after pulpotomy and pulp covering with mineral trioxide aggregate or Portland cement. *Braz Dent J* 2001;12(2):109-13.

57. Dominguez MS, Witherspoon DE, Gutmann JL, Opperman LA. Histological and scanning electron microscopy assessment of various vital pulp-therapy materials. *J Endod* 2003;29:324-33.

58. Aeinehchi M, Eslami B, Ghanbari HA, Saffar AS. Mineral trioxide aggregate (MTA) and calcium hydroxide as pulp-capping agents in human teeth: a preliminary report. *Int Endod J* 2003;36:225-31.

59. Tziifas D, Pantelidou O, Alvanou A, Belibasakis G, Papadimitriou S. The dentinogenic effect of mineral trioxide aggregate (MTA) in short-term capping experiments. *Int Endod J* 2002;35:245-54.

60. Mitchell PJ, Pitt Ford TR, Torabinejad M, McDonald F. Osteoblast biocompatibility of mineral trioxide aggregate. *Biomaterials* 1999;20(2):167-73.

61. Faraco IM Jr, Holland R. Response of the pulp of dogs to capping with mineral trioxide aggregate or a calcium hydroxide cement. *Dent Traumatol* 2001;17(4):163-6.

62. Holland R, de Souza V, Nery MJ, Otoboni Filho JA, Bernabe PF, Dezan Junior E. Reaction of rat connective tissue to implanted dentin tubes filled with mineral trioxide aggregate or calcium hydroxide. *J Endod* 1999;25(3):161-6.

63. Torabinejad M, Hong CU, Pitt Ford TR, Kettering JD. Antibacterial effects of some root end filling materials. *J Endod* 1995;21:403-6.

64. Torabinejad M, Rastegar AF, Kettering JD, Pitt Ford TR. Bacterial leakage of mineral trioxide aggregate as a root-end filling material. *J Endod* 1995;21:109-12.

65. Fischer EJ, Arens DE, Miller CH. Bacterial leakage of mineral trioxide aggregate as compared with zinc-free amalgam, intermediate restorative material, and Super-EBA as a root-end filling material. *J Endod* 1998;24:176-9.

66. Lee SJ, Monsef M, Torabinejad M. Sealing ability of a mineral trioxide aggregate for repair of lateral root perforations. *J Endod* 1993;19:541-4.

67. Martell B, Chandler NP. Electrical and dye leakage comparison of three root-end restorative materials. *Quintessence Int* 2002;33(1):30-4.

68. Tang HM, Torabinejad M, Kettering JD. Leakage evaluation of root end filling materials using endotoxin. *J Endod* 2002;28:5-7.

69. Adamo HL, Buruiana R, Schertzer L, Boylan RJ. A comparison of MTA, Super-EBA, composite and amalgam as root-end filling materials using a bacterial microleakage model. *Int Endod J* 1999;32:197-203.

70. Fogel HM, Peikoff MD. Microleakage of root-end filling materials (published correction appears in *J Endod* 2001;27:634). *J Endod* 2001;27:456-8.

71. Torabinejad M, Higa RK, McKendry DJ, Pitt Ford TR. Dye leakage of four root end filling materials: effects of blood contamination. *J Endod* 1994;20:159-63.

72. Koh ET, Ford TR, Kariyawasam SP, Chen NN, Torabinejad M. Prophylactic treatment of dens evaginatus using mineral trioxide aggregate. *J Endod* 2001;27:540-2.

73. Hafez AA, Cox CF, Tarim B, Otsuki M, Akimoto N. An in vivo evaluation of hemorrhage control using sodium hypochlorite and direct capping with a one- or two-component adhesive system in exposed non-

human primate pulps. *Quintessence Int* 2002;33:261-72.

74. Cohen S, Burns RC, eds. *Pathways of the pulp*. 7th ed. St. Louis: Mosby; 1998:808-11.

75. Heys DR, Heys RJ, Cox CF, Avery JK. The response of four calcium hydroxides on monkey pulps. *J Oral Pathol* 1980;9:372-9.

76. Mjor IA. *Pulp-dentin biology in restorative dentistry*. Chicago: Quintessence; 2002.

77. Hirschfeld Z, Bab I, Tamari I, Sela J. Primary mineralization of dentin in rats after pulp capping with calcium-hydroxide. *J Oral Pathol* 1982;11:426-33.

78. Matsuo T, Nakanishi T, Shimizu H, Ebisu S. A clinical study of direct pulp capping applied to carious-exposed pulps. *J Endod* 1996;22:551-6.

79. Murray PE, Hafez AA, Smith AJ, Cox CF. Identification of hierarchical factors to guide clinical decision making for successful long-term pulp capping. *Quintessence Int* 2003;34(1):61-70.

80. Wu MK, Kontakiotis EG, Wesselink PR. Long-term seal provided by some root-end filling materials. *J Endod* 1998;24:557-60.

81. Roy CO, Jeansonne BG, Gerrets TF. Effect of an acid environment on leakage of root-end filling materials. *J Endod* 2001;27(1):7-8.

82. Blanco L, Cohen S. Treatment of crown fractures with exposed pulps. *J Calif Dent Assoc* 2002;30:419-25.

83. Mass E, Zilberman U. Clinical and radiographic evaluation of partial pulpotomy in carious exposure of permanent molars. *Pediatr Dent* 1993;15:257-9.